



# VASER-Assisted High-Definition Liposculpture



COLOMBIA

**Alfredo E. Hoyos, MD; and John A. Millard, MD**

Dr. Hoyos is in private practice in Bogota, Colombia and is a member of the Colombian Society of Plastic, Aesthetic, Maxillofacial, and Hand Surgery, Dr. Millard is in private practice in Lone Tree, CO.

**Background:** The introduction of VASER (vibration amplification of sound energy at resonance) technology has enabled the application of lipoplasty techniques to the superficial fat layers. Differential lipoplasty has been used to detail abdominal musculature by “abdominal etching,” but was applicable only to limited areas in male patients with low body fat.

**Objective:** The authors report on the use of VASER-assisted high-definition liposculpture to not only improve body contour but also to highlight the 3-dimensional muscular anatomy in a wide variety of patients.

**Methods:** After deep and superficial infiltration, emulsification was performed using VASER technology in continuous mode for high debulking and in pulsed mode at lower power for more delicate areas and the immediate subdermal plane. Debulking was performed using ventilated cannulas, beginning in the deep layers and continuing to the mid-lamellar layer and between muscle groups. Superficial emulsification was performed to define the relevant anatomy for the muscle groups in each treatment area. Transitioning was then performed to define the superficial anatomy landmarks by debulking some of the remaining fat over the muscles and smoothing the surfaces over the mid-lamellar area.

**Results:** A total of 306 patients were treated in two separate series; 281 by the senior author (AEH) and 25 by the co-author (JAM) Satisfactory results were obtained in 257 patients (84%). No cases of skin necrosis occurred. Minor complications included 20 cases of seroma, 9 cases of port site burns, and 5 cases of prolonged swelling.

**Conclusions:** VASER-assisted high-definition liposculpture is an aggressive approach to body contouring that enables the surgeon to perform body sculpting of the superficial tissues to define the 3-dimensional surface musculature in a wide range of patients. However, it is a difficult and time-consuming procedure with a high learning curve that is appropriate only for highly experienced surgeons. (Aesthetic Surg J 2007; 27:594–604.)

Although lipoplasty is currently the plastic surgical procedure performed most often in the United States,<sup>4</sup> the fundamental technique and technology have changed only slightly during the past 30 years. Performance of superficial lipoplasty with standard lipoplasty cannulas, as reported by Souza Pinto, Gasperoni and Gasparotti<sup>2,5-10</sup> expanded the boundaries of body contouring by enabling the removal of fat from the superficial layers. However, this advance in lipoplasty technique also involved increased risk of scarring, waviness, and contour irregularities, as well as cutis marmorata when excessive fat removal was performed. These issues led to various recommendations to avoid over-resection such as sparing 1 cm from the dermis.<sup>11-16</sup>

Scuderi et al<sup>11</sup> and Zocchi<sup>17,18</sup> published some of the earliest reports on ultrasound-assisted lipoplasty (UAL). The UAL device broke down fat cells to produce an emulsion, leading to a less traumatic procedure. However, the technological limitations of UAL resulted in a high incidence of complications, such as burns, skin necrosis, and

scarring<sup>19-21</sup>. Despite later improvements, including changes in the design of the tips and the development of hollow UAL-integrated probes rather than solid probes, the energy applied to the tissues was still too high for safe use for extended periods of time or in proximity to the skin. Schefflan and Tazi<sup>22</sup> reported the superficial application of ultrasound energy to produce “skin stimulation” for purposes of retraction was associated with burns, scarring, waviness and contour irregularities.

Jewell et al<sup>23</sup> first reported on the clinical application of a third-generation ultrasound lipoplasty device that utilized pulsed low-power ultrasound and high-efficiency, small-diameter solid titanium probes: VASER (vibration amplification of sound energy at resonance) lipoplasty. The energy applied to the tissues was approximately one-quarter that of previous devices, while the pulsed mode reduced heat generation. Expanded applications of VASER lipoplasty include treatment of the male and female breast, face and neck; fibrous body areas (trunk and back), and combined excisional body con-

touring procedures of all types (Jewell, Santa Fe Breast and Body Contouring Symposia 2006). Through these applications, VASER was confirmed as an enabling technology to address the superficial fat layer.

Mentz and Ersek<sup>24,25</sup> pointed out that traditional lipoplasty techniques often fail to achieve the aesthetic goal of a “washboard” abdominal contour because “subdermal fat obscures the muscular detail.” The Mentz technique called “abdominal etching” used differential lipoplasty to detail abdominal musculature, specifically the rectus abdominis muscle, between the linea alba and the linea semilunaris, while also addressing the tendinous inscriptions (intersectiones tendineae) of the rectus abdominis muscle. However, abdominal etching was designed specifically for male body builders with between 8% and 15% body fat, and was limited to only the anterior abdominal wall.

In 2003, Hoyos presented a significant improvement in technique at a Colombian National Congress,<sup>26</sup> which embodied a new approach to body contouring that he termed “high definition liposculpture” (HDL). The term “liposculpture”<sup>27</sup> defined the technique as not simply fat removal but as an artistic approach designed to emulate surface anatomy. As Gasparotti mentioned: “*I recognized that working superficially I had the ability to go well beyond the simple removal of fatty bulges . . . Why not use it as a sculpting tool to obtain the imaginary shape, the ideal profile we dream about creating?*”<sup>2</sup> HDL was developed through the study of art and anatomy of the human musculature, as an artistic treatment of the human form to create not only a slim figure, but also the appearance of a highly developed musculature.

High-definition liposculpture elevates the Mentz concept of abdominal etching to a 3-dimensional approach, taking into account the contributions made by other muscle groups to integrate the entire torso, legs and back. The differing aesthetic goals of male and female body contouring are integrated into this method, as are key areas such as the pectorals in men and the gluteal area in women. However, the potential benefits of HDL alone could be achieved only by highly-trained surgeons, while the technique itself was exhausting for the surgeon and very painful and traumatic for the patient. Adverse consequences of the procedure included a very slow healing time and prolonged swelling, which in turn required close, long-term follow up by the surgeon to avoid complications and undesirable results.<sup>26</sup>

The combination of VASER and HDL represents a marriage between technology and technique that allow a more precise, less traumatic procedure and improved

outcomes. VASER -assisted HDL (VAHDL) allows the fat to be prepared like an artist’s clay through emulsification, so that the surgeon can “sculpt” muscular anatomy in great detail through gentle extraction aspiration that minimizes the trauma normally associated with traditional lipoplasty.

VAHDL embodies the ultimate understanding of how superficial anatomy influences external appearance. Developed through the study of “surface anatomy” of human musculature much as an artist would view the human form,<sup>28-30</sup> VAHDL begins where superficial lipoplasty ends. VAHDL highlights the importance of contributions made to the aesthetics of the human form by both the superficial and deep fat layers when these layers are properly proportioned both between and over the muscle groups. What makes VAHDL different is that we use the underlying structures as a guide to contrast the various structures that make up the 3-dimensional body contour.

## Material and Methods

VAHDL is both more difficult and more time consuming than traditional (deep) lipoplasty. Several new steps have been added to accomplish the result. Compared to traditional lipoplasty, the addition of VASER for emulsification adds one extra step. Superficial fat removal adds an additional step.<sup>3</sup> Finally, VAHDL requires selective fat retention and fat removal from both the superficial and deep fat layers to achieve a natural 3-dimensional muscular appearance. This requires a good 3-dimensional eye on the part of the surgeon and much greater attention to detail than traditional lipoplasty.

## Patient selection

Patients were seen in consultation where a detailed medical history was first taken. Because VAHDL is designed to be a sculpting procedure rather than a debulking technique, appropriate patients were selected for good muscle tone without an excessive amount of fat or skin laxity (BMI < 30). A discussion of the patient’s wishes regarding physical activity as well as about goals and frustrations with respect to their fitness objectives with exercise alone was undertaken.

Once the physical examination was complete, lipodystrophy throughout the trunk was assessed, including documentation of the thickness of the extra-abdominal and trunk fat as well as contribution made by intra-abdominal fat, and assessment of muscle mass, musculo-fascial laxity, and rectus diastases. Patients were asked to perform various muscle contractions to aid in the examination of those separate muscle groups that contribute to

the contour of the torso. Finally, skin laxity, elasticity, and quality were noted.

In the male patient, the chest examination included assessment of gynecomastia and contribution to chest contour and volume by fat or lack of it. In the female patient, a similar assessment was undertaken of the buttocks, lumbosacral angle, and fat disposition in the lateral thighs and perigluteal area. Waist contour in the female patient was assessed by comparing the contour as defined by the musculoskeletal system versus the deep and superficial fat. The physical examination included documentation of adherent scars, hernias and other routine findings.

Upon completion of the history and physical examination, patients were shown a presentation explaining the procedure and showing the differences and results obtained by traditional SAL and VASER-assisted lipoplasty (VAL) and those obtained by VAHDL. If the patient's goals and expectations could be fulfilled by VAHDL and the physical examination made him or her a candidate for this technique, the patient was given approval for VAHDL and informed consent was obtained.

### Preoperative preparations

Standard laboratory tests were performed for all patients and were within normal ranges, Electrocardiograms and thoracic radiographs were taken in patients more than 40 years old. Either general or epidural

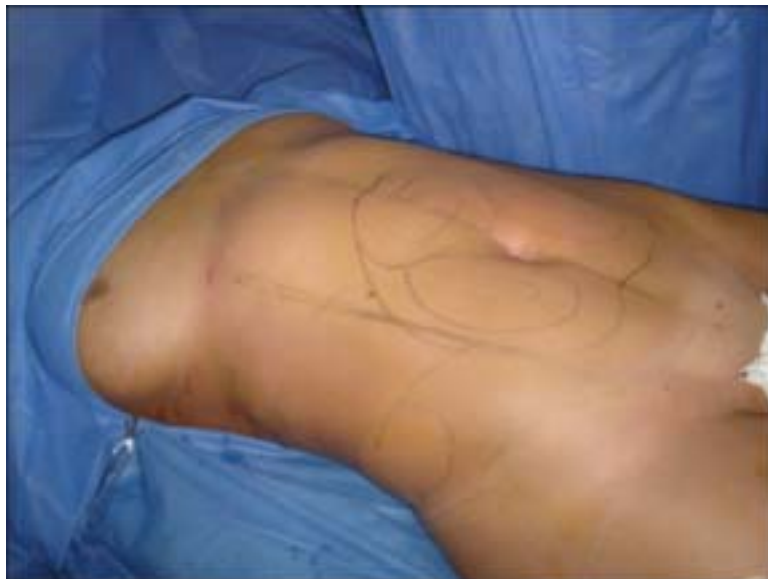anesthesia was used. Potential loss of body temperature was addressed by using a warmed solution (intravenous and infiltration), and heating blankets. Thromboembolism prophylaxis included low-weight heparin, intravenous corticosteroids, and compression devices on the legs.

All patients received 2 g of cefazolin, 8 mg of dexamethasone, 8 mg of ondansetron, 75 mg diclofenac, and 50 mg of tramadol during the surgery. This regimen was administered within the first hour of surgery; if the surgery continued for more than 3 hours, another 2 g of cefazolin was administered.

### Surgical technique

The senior author (AEH) operated on 281 patients between February 2005 and February 2007, including 264 women (ages 17-70) and 17 men (ages 18-65). The co-author (JAM) operated on 25 patients between January 2006 and February 2007, including 9 women (ages 26-45) and 16 men (ages 24-62).

**Preoperative marking.** The first and key step was the surgical marking (Figure 1). This was performed with the patient initially supine and completed with the patient in the upright standing position. An understanding of superficial anatomy and topography is mandatory; the surgeon must learn how to examine the patient for individual characteristics. Inaccurate marking will lead to deformities and abnormal appearance.



**Figure 1.** Preoperative view of a patient in the operating room, showing preoperative markings.

The surface anatomy varies between men and women. In women, the transversal lines in the rectus abdominis muscle are not aesthetically desirable, because they tend to look too “masculine.” In men, the landmarks marked were the pectoralis major, serratus anterior, rectus abdominis, external oblique, iliac crest and inguinal ligaments and the relationship between those structures. The “V” shape is desirable in the male back, as is a convexity over the inferior portion of the obliquus muscle. In women, the landmarks were the serratus anterior, rectus abdominis, external oblique, iliac crest, and inguinal ligaments. The lateral and posterior torso anatomy is also important; that is, the gluteus maximus, paraspinal muscles along the sides of the column, sacral concavity, and the perigluteal area.

**Infiltration.** Both superficial and deep infiltration were performed using a standard solution of 1000 mL of normal saline and 1 ampule of epinephrine 1:1000, with symmetric volumes infiltrated on each side. The infiltration-aspiration ratio was 1.5-2:1. Detailed infiltration was performed in areas that required more superficial work, such as the waist and perigluteal area in women, the indentations of the rectus and serratus muscles in men, and the areas of skin laxity such as the hypogastrum. In anticipation of VASER use, the exact amounts of infiltration in each area and the estimated time of VASER use were recorded on a chart. An estimated 10 minutes were allotted after infiltration before the commencement of VASER emulsification in order to allow time for effective vasoconstriction.

**Emulsification.** Emulsification was performed in accordance with the chart of volume infiltrated, in the same order as the infiltration. The duration of VASER treatment was 1 minute per each 100 mL of infiltration, but the clinical endpoint was the loss of resistance. Areas of high debulking, such as large fat deposits, were treated with a 3.7-mm or 2.9-mm 3-groove probe, at 80% power in continuous mode. The back and posterior arms were treated using a 3.7-mm 1-groove probe in continuous mode. Thin skin or delicate areas, such as the inner thighs, waist, and neck, were treated using a 2.9-mm 3-groove probe at 60% power in pulsed mode. Differential emulsification was performed for each muscle group and the muscle lines. Superficial emulsification was performed using a 2.9-mm 3-groove probe, always in pulsed mode (in some cases additional infiltration was performed prior to the superficial emulsification). It is the superficial emulsification that addresses the immediate subdermal plane, thus allowing enhanced skin retraction, and compensating for areas of muscle or fascial laxity,

such as those encountered in the hypogastrum. The emulsification focused on the three lamellar layers, as described by Avelar.<sup>1</sup> The clinical endpoint in superficial layer emulsification was also the loss of resistance, but the skin was never allowed to become warmer than the hand of the surgeon. The achievement of loss of resistance in this layer without heat generation is key to avoiding complications.

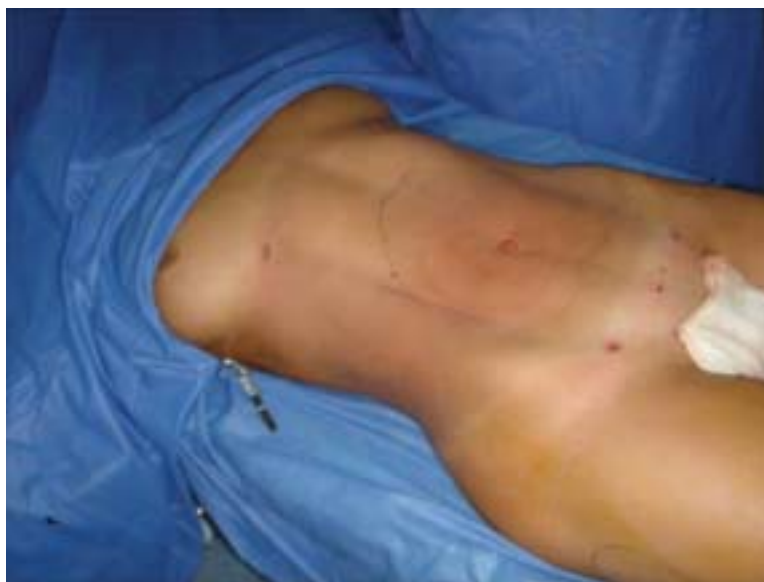**Debulking.** Atraumatic VentX cannulas (Sound Surgical Technologies, Louisville, CO) are used for debulking. These cannulas are “ventilated” with specially designed small holes to prevent clogging, achieve optimal efficiency, and provide gentle suction that minimizes trauma.<sup>31</sup> Debulking began at the areas of fat deposits in the deep layer, using 3.7-mm or 4.6-mm cannulas, and continued in the mid-lamellar layer and between muscle groups, avoiding aspiration against the delicate subdermal layer.

**Superficial emulsification and extraction.** These steps were performed selectively over the muscular frame in each area to define relevant anatomy for each muscle group (ie, linea alba and its tendinous insertions, the pectoral inferior line, inguinal ligament), using a 2.9-mm probe emulsification and 3.0-mm cannula aspiration. Superficial emulsification and extraction were performed in the subdermal lamellar layer. From an artistic point of view, this step is analogous to the initial 2-dimensional sketch of any drawing.

**Transitioning.** This technique is defined as the blending of the framing and topography of the muscles. Using a 3.7-mm or 4.6-mm cannula, some of the remaining fat over each of the muscles was debulked, while the surface overlying the creases over the mid-lamellar layer was smoothed, thus improving the definition of the superficial anatomy landmarks. Transitioning create the natural but well-defined appearance that we sought to achieve. From an artistic point of view, this step is equivalent to the addition of “shadows and light” to created a 3-dimensional “rendering” (Figure 2). The surgical endpoint was the definition of the lateral borders of the muscles while retaining a thin layer of fat (1 cm in a pinch test).<sup>12</sup>

### Postoperative management and course

Open drains (small Jackson-Pratt-type drain cut short, without suction) were left for 48 to 72 hours in the sacral area in female patients or in the inguinal area in male patients. Postoperative care included the use of a mild-compression garment, deep vein thrombosis (DVT) stockings, and a cotton-laminated soft foam band of our



**Figure 2.** Intraoperative view after framing and transitioning to obtain a 3-dimensional appearance.

own design for a period of 4 weeks. Patients were given oral antibiotic and anti-inflammatory drugs for a short period of time. After 48 hours, patients were allowed to start postoperative lymphatic drainage massages and adjunctive external ultrasound (1-hour session once a day for 10 days).

Patients were followed postoperatively at 1, 3, 6, 12 and 24 weeks. The definition accomplished at surgery was lost in the early initial postoperative period because of swelling but started to re-emerge at 3 to 4 weeks postoperatively. Patients also experienced indurations during the first 6 to 8 weeks postoperatively that tended to be migratory, particularly in areas of definition where contour was created by superficial and transitioning work. In all cases these indurations disappeared completely by the third month. Patients also experienced cyclic swelling that varied the appearance of definition throughout the day. At approximately 4 months postoperatively, the swelling abated and patients could see about 95% of their final results and definition.

### Results and complications

Satisfactory results were achieved in 257 patients (84%). Typical results are illustrated in Figures 3 to 6.

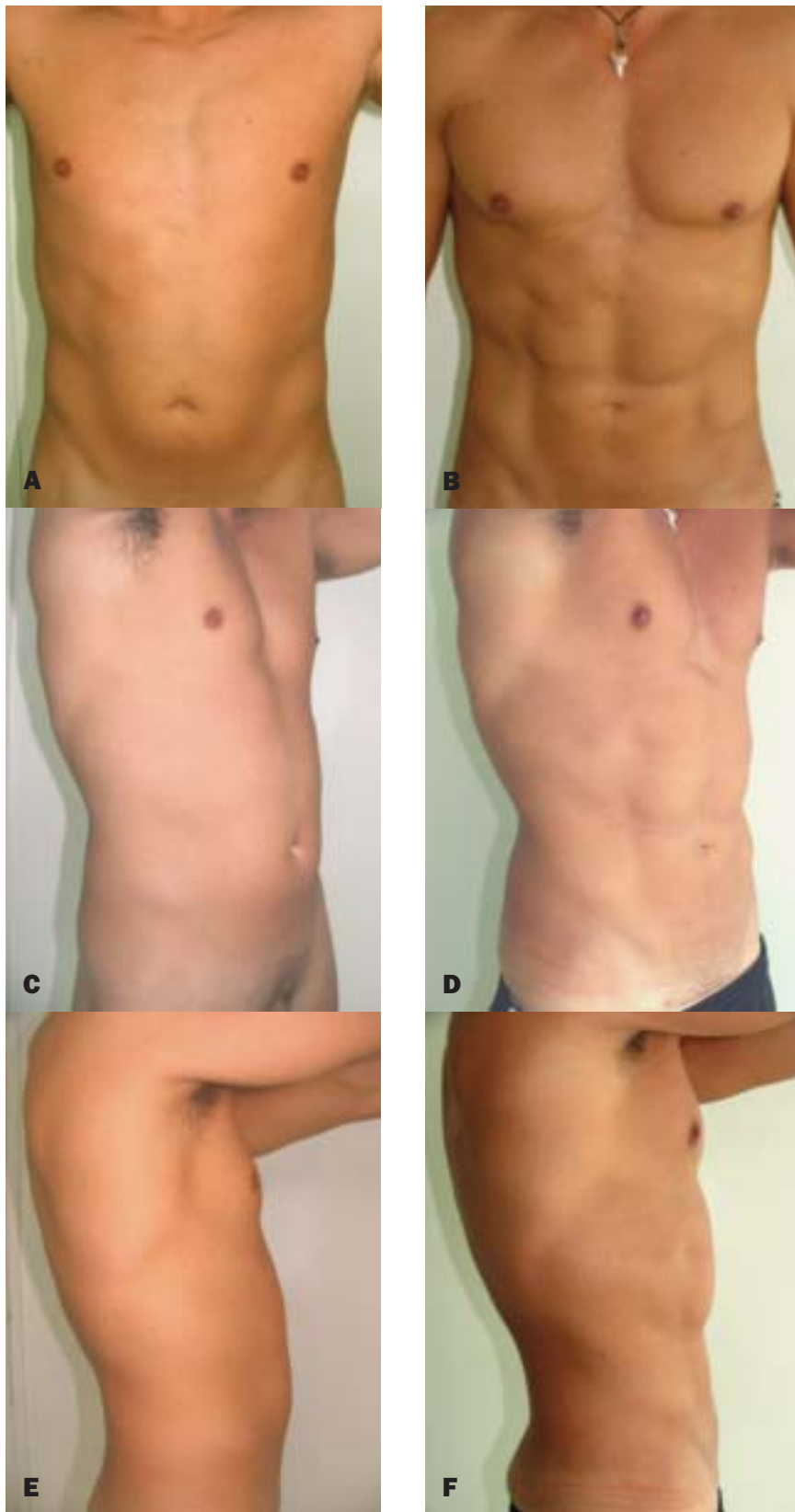
Complications included seromas in 20 patients; the incidence of seroma decreased dramatically with the use of drains in the sacral area in female patients and in the inguinal area in male patients (Table). All seromas

responded to percutaneous drainage without the need for surgical treatment. Infections at port sites occurred in 2 patients and were successfully treated with oral antibiotics and local wound care. Secondary procedures were required to correct contour irregularities in 10 patients, 8 of whom had undergone previous lipoplasty. Residual skin laxity requiring excisional surgery occurred in 6 patients.

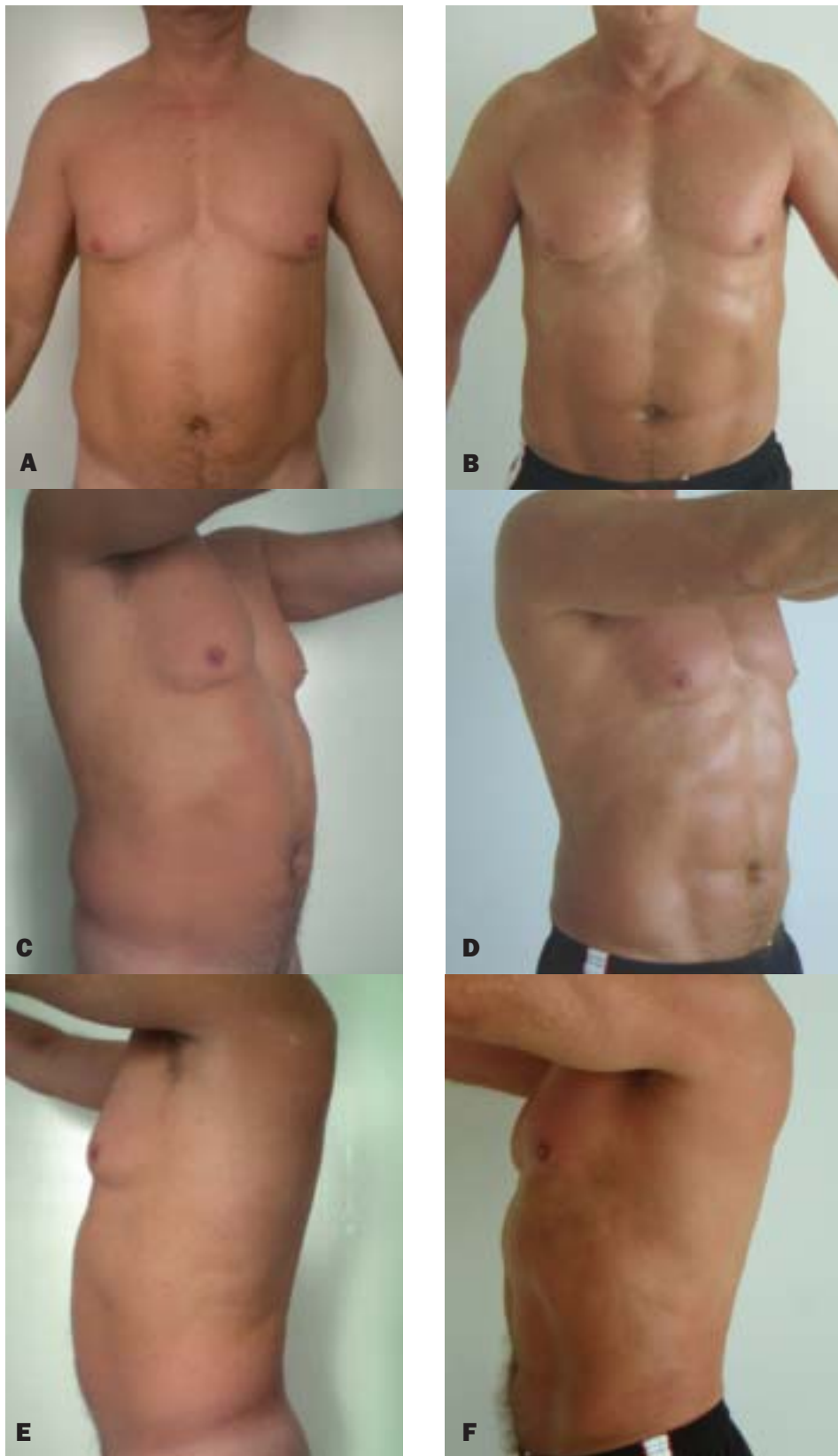
One patient had an area of induration in the inner thighs 1 week after surgery, initially confused with cellulitis, but no redness or high temperature was present in the area. It resolved spontaneously within 2 weeks. A check of the surgical chart revealed that high power was used in this area (80% continuous mode). No such induration occurred when the low power-pulsed mode (60%) was used. Initial burns in the port areas seen by the senior author were attributed to the learning curve. After using selective infiltration in these areas (5 cc on each skin port area with a 23-gauge syringe) before placing the ports, no further burns occurred. Pigmentary changes were observed in 2 patients in the inner thighs, overresection was diagnosed in both cases.

Minor complaints were seen as follows: generalized low fat extraction that required revision in 9 patients; localized residual fat deposits, especially in the hypogastrium, creating a “pooch” appearance in 12 patients that required revision; persistence of definition during pregnancy in 1 patient; and low definition confirmed by the surgeon in 12 patients, only 4 of whom required revision.

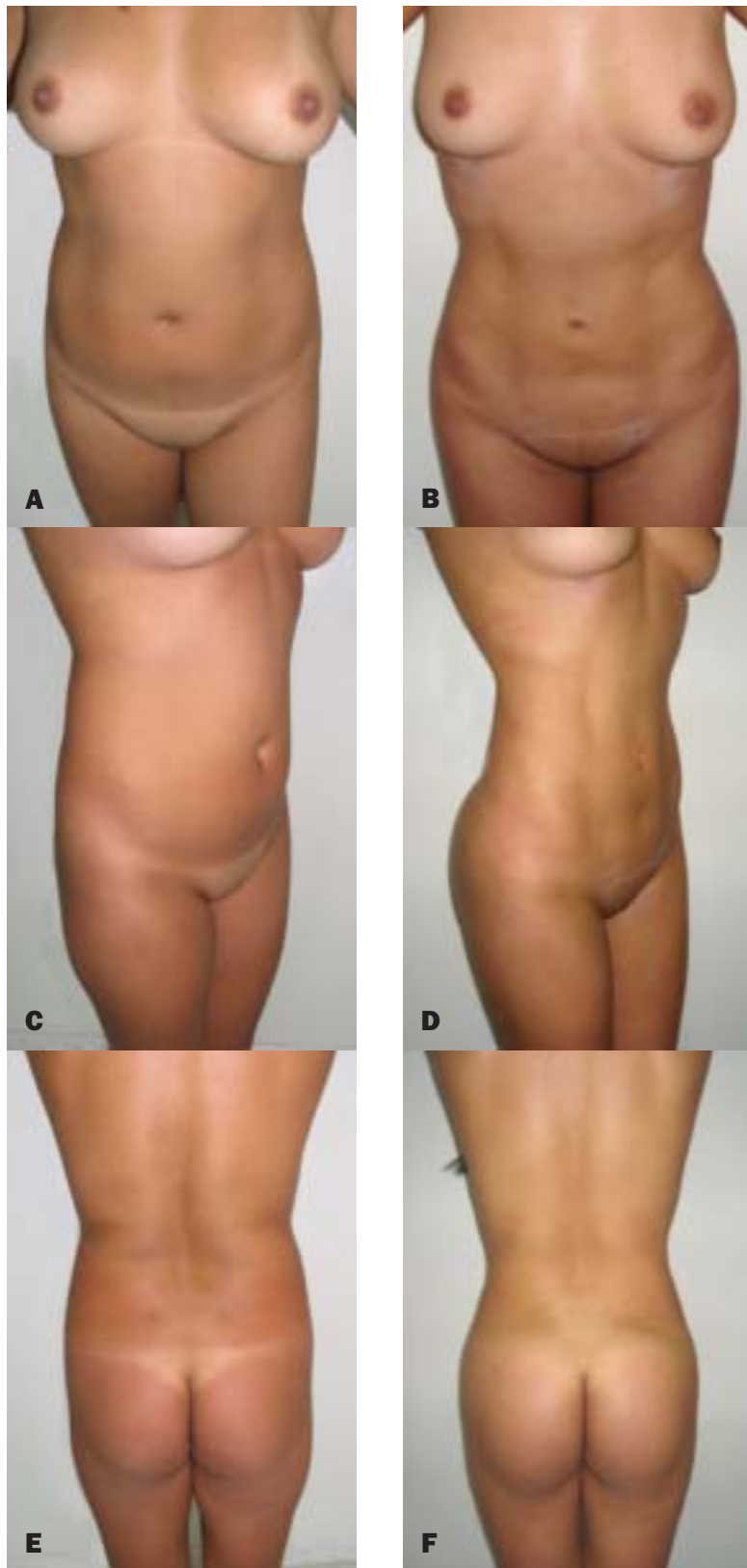




**Figure 3. A, C, E,** Preoperative views of a 32-year-old man. **B, D, F,** Postoperative views 6 months after VAHDL plus fat grafting in the pectoral area, 150 mL on each side. Notice the high definition of the rectus abdominis obliques and pectoralis, latissimus dorsi, and the obliques and serratus.

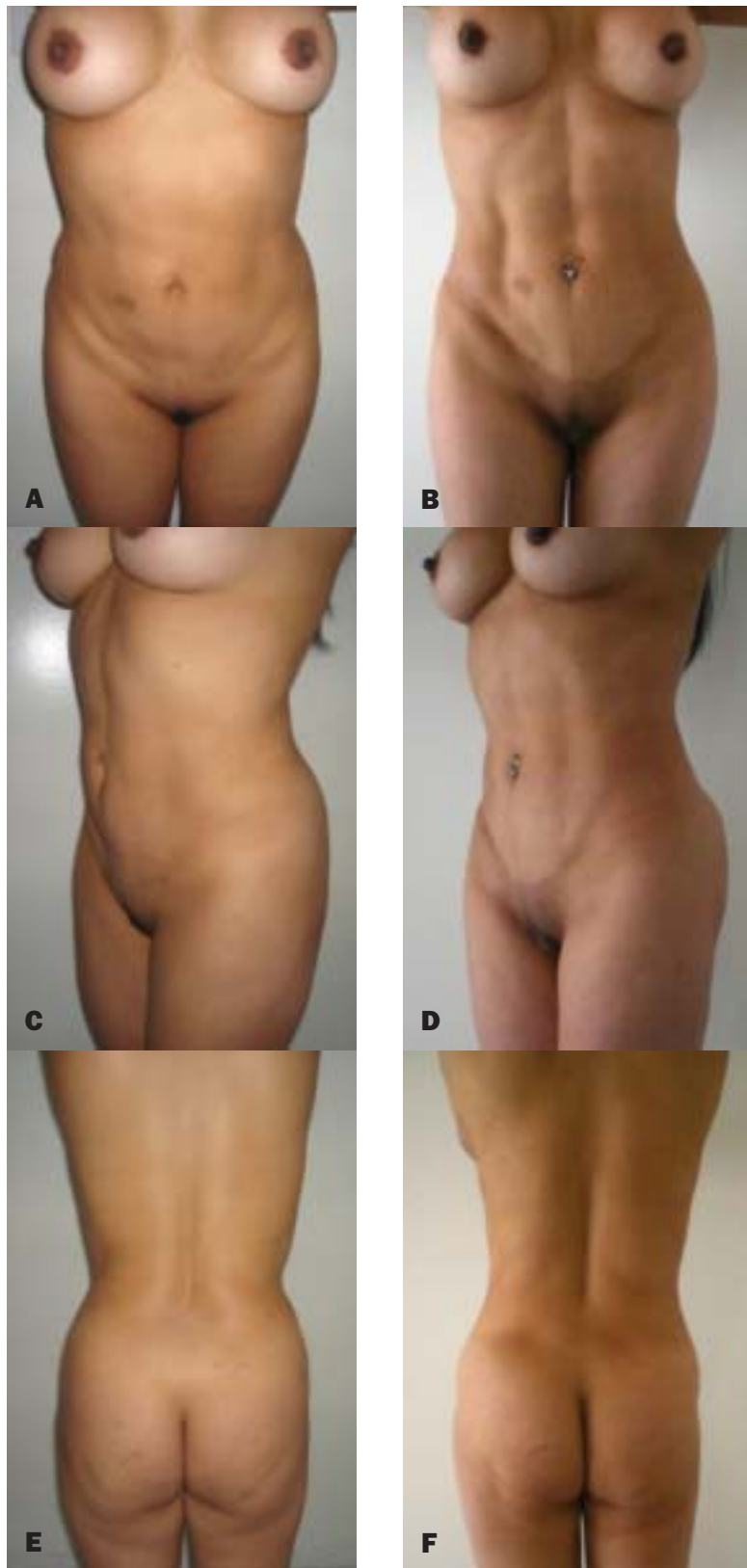


**Figure 4.** **A, C, E,** Preoperative views of a 60-year-old retired male athlete. **B, D, F,** Postoperative views 6 months after VAHDL. Despite the patient's age, notice the high muscular definition of the rectus abdominis the obliques, and the pectoralis.



**Figure 5. A, C, E,** Preoperative views of a 30-year-old moderately obese woman. **B, D, F,** Postoperative views 3 months after VAHDL plus fat grafting in buttocks, 350 mL on each side. Notice the high muscular definition of the rectus abdominis, the concavity in the lower lateral border of the rectus, the waist contour and the perigluteal area, as well as the overall athletic yet feminine appearance.





**Figure 6. A, C, E,** Preoperative views of a 36-year-old woman with stretch marks and relatively high skin laxity. **B, D, F,** Postoperative views 2 years after VAHDL. Notice the high muscular definition of the rectus abdominis, the concavity in the lateral border of the lower rectus, the waist concavity, the sacral dimples, and the residual skin laxity in the lower perigluteal area.

**Table. Complications**

Complication	Surgeon 1 (n = 281)	Surgeon 2 (n =25)
Seroma	14	6
Induration	1	0
Alteration of sensation	0	0
Port site burns	9	0
Distant burns	0	0
Cellulitis / infections	2	0
Skin necrosis	0	0
Pigmentary changes	2	0
Prolonged swelling	5	0

### Discussion

Traditional lipoplasty techniques incorporate deep lipoplasty and wet techniques in order to prevent contour irregularities. A subdermal fat pad is necessary to prevent wrinkling and contour irregularities.<sup>12,16</sup> However, these techniques cannot accomplish the higher aesthetic goals imposed by the media and modern standards of beauty.

Treatment of the superficial layers is necessary to achieve optimal aesthetic results. Conventional superficial SAL and PAL produced contour irregularities, hyperpigmentation, and waviness when used in the superficial layer. UAL has been associated with severe burns and other complications<sup>19, 20-22, 32</sup> when used on the surface.

VAL uses less energy than second-generation UAL (second-generation devices had a high heat release to the tissues caused by the high levels of power necessary to make them work efficiently).<sup>34</sup> In addition, VAL does not remove the protective wetting solution during fragmentation because it uses a solid probe.<sup>35</sup> These technical advances reduce the risk of complications, such as burns and skin necrosis. When used for superficial work, VASER has proven to be a safe and exacting technology.

Hoyos described HDL as a precision technique,<sup>26</sup> involving a 3-dimensional multilayer concept of body contouring, which allows better results, but eradicates the concept of body contouring by sectors (it is “all or nothing lipoplasty”). Using this technique, we achieved results superior to abdominal etching, precisely because the entire torso was addressed the female contour also could be addressed. HDL expanded the range of patients to include those with more than 15% body fat and women, in contrast to the etching technique restricted to only body builders.<sup>24,25</sup> Hoyos used this technique for 4 years with fine results, but patients experienced a very painful, traumatic recovery, especially in the zones of superficial work. In addition, because it was more traumatic, HDL involved

comparatively more bleeding and less extraction. (HDL alone produced 65% to 75% fat in the suction canister, compared to 80% to 95% in the VAHDL. This restricted the use of HDL to young, healthy and highly motivated patients. Finally, the learning curve for the procedure was very high, because of the required finesse and accuracy.

The introduction of third-generation ultrasound that enabled the evolution of HDL into VAHDL increased the number of surgical steps and time of surgery. But the exactitude achieved by quantifying every step of the process (infusion volume, ultrasound time, and extraction volume) provides an accuracy and symmetry never achieved by other methods. This factor is very important for the surgeon, not withstanding that VAHDL requires greater attention to detail than traditional lipoplasty.

VAHDL provides a faster and less painful recovery than HDL: on a scale 1 to 5, with 1 = no pain and 5 = maximum pain, HDL was between 4-5, VAHDL 3-4. The degree of patient satisfaction with VAHDL is far superior to that of standard lipoplasty or VAL techniques, since in most patients (84%) it achieves a natural, highly athletic-looking result with enhanced contour definition and skin tightening.

As we are “pushing the envelope” of surgical possibilities with VAHDL, higher complication rates are expected than those previously published by Jewell et al.<sup>23</sup> In particular, the incidence of seroma is higher because of the superficial layer work performed; we encountered 20 seromas (6.5%) vs. 0%. Nevertheless, this rate is low compared to UAL (21.8%)<sup>20</sup>; the use of drains minimized the incidence of seroma. Port skin burns were also higher (2.94% vs. 0%), but infiltration in the skin port area reduced this incidence. None of the serious complications associated with UAL—distant burns or skin necrosis—were observed in our series.<sup>23</sup>

### Conclusion

VAHDL is more difficult and time-consuming than traditional lipoplasty, and requires a comprehensive understanding of how skin, fat, muscle and skeletal structures contribute to the 3-dimensional superficial topography of the male and female human form. However, it represents a significant advance in body contouring in that it addresses the entire torso musculature and the female body contour. VAHDL also opens up a whole new demographic of patients who would not have previously considered body contouring, and may become a means for achieving body sculpting results that previously were attainable only through diet and exercise.

We believe that this aggressive approach achieves superior outcomes and an acceptable rate of complica-

tions and revisions, avoiding problems associated with UAL.<sup>19,20-22,32</sup> The fragmentation of all the deep, intermediate, and subdermal lamellae is gentle and exacting, without the rate of complications usually seen in multi-layer techniques<sup>1</sup>. We believe that VASER is an enabling technology<sup>23</sup> in VAHDL. With further study, these same principles may soon be applied to define muscle groups in many other areas of the body. ■

*The authors would like to acknowledge and thank William W. Cimino, PhD, for sharing his theories and techniques of application of the VASER to the superficial layer, his theories of skin retraction based on load-sharing in layers and volume depletion, and his review and comment on this manuscript.*

*Dr. Hoyos is a consultant for Sound Surgical Technologies, manufacturer of VASER, serving as a speaker and as a teacher. He receives reimbursement for travel expenses and compensation for time out of the office. Dr. Millard has no financial interests in and receives no compensation from manufacturers of products mentioned in this article.*

## References

- Avelar, J. Regional Distribution and Behavior of the Subcutaneous Tissue Concerning Selection and Indication for Liposuction. *Aesthetic Surg J* 1989; 13:155-165.
- Gasparotti M, Lewis CM. Superficial Liposculpture: Manual of Technique. Springer-Verlag 1990; New York, N.Y
- Gasparotti M. Superficial Liposuction: A New Application of the Technique for Aged and Flaccid Skin. *Aesth Plast Surg* 1992;16: 141-5
- Matarasso, Alan M.D.; Swift, Richard W. M.D.; Rankin, Marlene Ph.D. Abdominoplasty and Abdominal Contour Surgery: A National Plastic Surgery Survey. *Plast Reconstr Surg* 117(6):1797-1808
- Gasperoni C. Suction-Assisted Lipectomy of the Subdermal Liposuction Fat Layer: Subdermal Liposuction. *Annals of the International Symposium. Recent Advances in Plastic Surgery* 1990;90:477
- Gasperoni C. Subdermal Liposuction. *Aesth Plast Surg* 1990;14: 137-142.
- Gasperoni C. Rationale of Subdermal Superficial Liposuction Related to the Anatomy of Subcutaneous Fat and the Superficial Fascial System. *Aesth Plast Surg* 1995;19:13-20.
- Gasperoni C. MALL Liposuction: The Natural Evolution of Subdermal Superficial Liposuction. *Aesth Plast Surg* 1994;18:253-257.
- de Souza Pinto EB, Indaburo PE, Da Costa Muniz A, Martinez YP, Gerent KMM, Iwamoto H, Marão Miziara AC. Superficial Liposuction: Body Contouring. *Clin Plast Surg* 1996;23(4):529-548.
- Gasparotti M. Superficial Liposuction for Flaccid Skin Patients. *Annals of the International Symposium. Recent Advances in Plastic Surgery* 1990;90:441.
- Scuderi N, Paolini G, Grippaudo FR, Tenna S. Comparative evaluation of traditional, ultrasonic, and pneumatic assisted lipoplasty: analysis of local and systemic effects, efficacy, and costs of these methods. *Aesthetic Plast Surg* 2000;24:395-400.
- Porto da Rocha, R. Cutis marmorata resemblance after liposuction. *Aesthetic Plast Surg* 2005 Jul-Aug;29(4):310-2.
- Porto da Rocha, R. Morphological Aspects of Dorsum and Sacrum Skin as Related to Liposuction. *Aesth Plast Surg* 2000;24:171-178.
- De Souza Pinto, EB. Morpho-Histological Analysis of Abdominal Skin as Related to Liposuction. *Aesth Plast Surg* 1997;21(3):153-158.
- Porto da Rocha, R. The Thigh's Lateral Skin (Saddle Bags): Histomorphological Study of Interest to Liposuction. *Aesth Plast Surg* 2000;24:155-160.
- Markman B, Barton FE. Anatomy of the Subcutaneous Tissue of the Trunk and Lower Extremity. *Plast Reconstr Surg* 1987;80(2): 248-254.
- Zocchi M.L. Ultrasound-assisted lipoplasty. *Adv. Plast Reconstr Surg.* 1995;11:197-221.
- Zocchi M.L. Ultrasound-assisted lipoplasty. Technical refinements and clinical evaluations *Clin Plast Surg* 1996;23:575-598.
- Zukowski, ML. Ultrasound-assisted Lipoplasty Learning Curve. *Aesthetic Surg J* 1998;18:104-110.
- Troilius, C. Ultrasound-Assisted Lipoplasty: Is It Really Safe? *Aesthetic Surg J* 1999;23:307-311.
- Ultrasound-Assisted Liposuction; Rod J. Rohrich, Samuel J. Beran, Jeffrey M. Kenkel; Quality Medical Publishing, Inc. 1998
- Scheflan, M., Tazi H. Ultrasonically assisted body contouring. *Aesthetic Surg J* 1996;16:117-122.
- Jewell ML, Fodor PB, de Souza Pinto EB, Al Shammari MA. Clinical Application of VASER-assisted Lipoplasty: A Pilot Clinical Study. *Aesthetic Surg J* 2002;22:131-146.
- Mentz H, Gilliland M, Patronella C. Abdominal Etching: Differential Liposuction to Detail Abdominal Musculature. *Aesth Plast Surg* 1993;17(4):287-290.
- Ersek RA, Salisbury AV. Abdominal Etching. *Aesth Plast Surg* 1997;21:328-331
- Hoyos AE. High Definition liposculpture. Presented in the XIII International Course of Plastic Surgery, Bucaramanga, Colombia, 2003.
- Fischer G. Liposculpture: the "correct" history of liposuction. Part I. *J Dermatol Surg Oncol.* 1990 Dec;16(12):1087-9
- Simblet S, Davis J. Anatomy for the Artist. DK Publishing 2001; New York, N.Y.
- Rubins DK. The Human Figure: An Anatomy for Artists. Penguin Books 1976; New York, N.Y.
- Schider, F. An Atlas of Anatomy For Artists. Dover Publications 1957; New York, N.Y.
- Fodor PB, Cimino WW, Watson JP, Tahernia A. Suction-Assisted Lipoplasty: Physics, Optimization, and Clinical Verification. *Aesthetic Surg J* 2005;25:234-246.
- Grolleau JL. Severe cutaneous necrosis after ultrasound lipolysis. Medicolegal aspects and review. *Ann Chir Plast Esthet.* 1997 Feb;42(1):31-6. French.
- Cimino WW, Bond LJ. Physics of Ultrasound Surgery Using Tissue Fragmentation: Part I. *Ultrasound Med Biol* 1996;22:89-100.
- Cimino WW. Ultrasound Surgery: Power Quantification and Efficiency Optimization. *Aesthetic Surg J* 2001;21:233-240.
- Cimino WW. The Physics of Soft Tissue Fragmentation Using Ultrasonic Frequency Vibrations of Metal Probes. *Clin Plast Surg* 199;26:447-461.

Accepted for publication July 20, 2007.

Reprint requests: Alfredo E. Hoyos, MD, Calle 119, #11D-30, Bogota, Colombia. E-mail: [alhoyos@gmail.com](mailto:alhoyos@gmail.com).

Copyright ©2007 by The American Society for Aesthetic Plastic Surgery, Inc. 1090-820X/\$32.00  
doi:10.1016.j.asj.2007.08.007